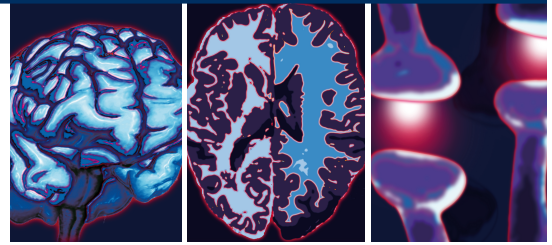


## CASE REPORT



# A diagnostic dilemma between psychosis, neuroleptic malignant syndrome and encephalitis

Anupam Verma\* & Angharad Ruttley

### Practice points

- NMDA receptor encephalitis may present with symptoms highly suggestive of psychiatric illness.
- Thorough organic screening is essential to ensure correct diagnosis and avoidance of delay in instating correct treatment.
- Psychomotor changes and dehydration act to increase the effects of neuroleptic malignant syndrome, further highlighting the importance of correctly identifying organic pathology in patients with anti-NMDA receptor encephalitis.
- Psychosocial factors play a critical role in perpetuating psychiatric and organic illness, as well as potential for recovery, and should be further explored, particularly if the diagnosis is unclear.

**SUMMARY** We describe the case of a patient presenting with symptoms highly suggestive of a psychotic illness. Prior to an organic assessment, antipsychotics were commenced at an early stage, causing neuroleptic malignant syndrome and contributing to confusion regarding the pathophysiology and etiology of the presentation. The chronology of symptoms was suggestive of a disease process prior to neuroleptic malignant syndrome and investigations subsequently confirmed anti-NMDA receptor encephalitis. The picture was further complicated by considerable psychosocial stressors, which were thought to have been contributory to perpetuation of the presentation. The case highlights the importance of close working relationships between psychiatry and neurology, and also the consideration of both organic and psychiatric pathology when patients present.

We describe the case of a 20-year-old woman of British–Asian origin who presented to her local accident and emergency (A&E) department following a change in her communication and behavior. Approximately 1 week prior to her initial presentation, the patient's family noticed that she had become less interactive and communicative than usual. She ceased speaking, and began to nod in response to questions. Over the

next 4 weeks, she was assessed by a number of healthcare professionals, during which time her symptoms steadily worsened. Her movements became notably slower, she required help feeding, would no longer shower or dress independently and seemed unable to brush her teeth. She had been observed maintaining rigid postures, making nonpurposeful noises and talking to herself. She re-presented to A&E and, upon assessment,

Department of Liaison Psychiatry, Charing Cross Hospital, Fulham Palace Road, London, UK  
\*Author for correspondence: anupam.verma@nhs.net

was thought to be suffering from either catatonia on account of apparent posturing or a conversion disorder suggested by the profound diminution of voluntary movements and responsiveness to external stimuli. She was initially taken on by a local crisis resolution team and commenced on aripiprazole. Her symptoms deteriorated further and she was subsequently admitted directly to a local mental health unit, where her blood tests revealed an elevated creatinine phosphokinase (CPK) level of 4000, and as well as this, she had a pyrexia. The chronology of most recent events indicated that her further deterioration occurred subsequently to the administration of an antipsychotic, and elevated CPK and pyrexia suggested a current presentation consistent with neuroleptic malignant syndrome (NMS).

She was transferred to the local district general hospital, where it was felt that NMS did not account for the entirety of the patient's presentation. Her symptoms had commenced approximately 1 month prior to receiving antipsychotics, and a second pathological process was therefore suspected. The admitting team sought a neurological opinion from the visiting tertiary service neurologist to address the period prior to the onset of NMS.

The neurologist proposed complex partial seizures, autoimmune and viral encephalitis, acute intermittent porphyria and Wilson's disease as potential differential diagnoses. The patient was transferred to the tertiary center, and the following investigations and referral for opinions were organized:

- Autoimmune encephalitis screen (anti-voltage-gated potassium channel antibodies, anti-NMDA receptor antibodies and anti-basal ganglia antibodies);
- Viral encephalitis screen (herpes simplex virus, varicella zoster virus, Epstein–Barr virus, cytomegalovirus, enteroviruses, hepatitis and HIV);
- Acute intermittent porphyria screen;
- Antistreptolysin antibody titers;
- Copper and ceruloplasmin;
- DaTSCAN;
- MRI of the brain with contrast MRI;
- CT scans of the chest, abdomen and pelvis;
- Liaison psychiatry opinion.

The neurology team referred to our service with the questions:

- Does the presentation now look psychiatric in origin?
- Is this a physical disorder presenting with psychiatric symptoms?

### Collateral history

During the course of the admission, we collected a detailed collateral history from the mother.

In the months leading up to her presentation, the patient had experienced several life stressors. She had a previous diagnosis of epilepsy and, following a change to her medication regimen, her seizures had returned after a symptom-free period of 2 years. Consequently, she was required to cease driving, something that she was devastated about. Alongside this, and unbeknown to her family, she had accrued debts of several thousand pounds while at university and had recently ended a relationship with a man who was disapproved of by her family. Premorbidly, she was a high achiever and had acquired a place on a competitive, largely male-dominated degree course and was achieving well. She attained good A-level results; however, her mother recalled that she required counseling around the time to help her cope with academic and social stressors. The collateral history suggested that, in the context of the aforementioned stressors that had been present over a 2-year period, the patient's psychological state had been deteriorating in the lead up to her presentation.

From our regular reviews of the patient and meetings with the family, they described their family as very closely knit. There were substantial tensions and conflicts within the family. The patient's mother held strong beliefs about various aspects of her family and daughter's lives, including her relationship with a man of a different religion to her own, which was disapproved of within the family. Another female relative had previously been excluded from the family unit because of relationship choices she had made. When the patient became unwell, it had emerged that she had also – again unbeknown to her family – run up significant debts at university, which had now been paid by her parents. In hospital, the patient's mother was present at the bedside for 12 h per day, despite prescribed visiting hours on the ward. She took on responsibility for much of the nursing care, including feeding and toileting.

### Mental state examination

The patient was a slim British–Asian female who lay motionless in bed with absent spontaneous

body movements – there were no movements of limbs and her eyes were wide open with no blinking; she showed occasional facial twitching. She showed an absence of instinctive and learned functioning, ate and drank only with prompting and was not able to self-dress or toilet. She showed no speech, only occasional phonation manifesting as a ‘moan’-like sound. She did not appear to be responding to any unusual stimuli. She was unable to participate in any tests of cognition.

### Psychiatric differential diagnoses

We felt that while neuroleptic malignancy syndrome had complicated the picture, there were symptoms that preceded this that were unlikely to be explained by a primary psychiatric disorder.

Our role was particularly to reinforce that further neurological investigations were required and to advocate for the patient to ensure that an organic etiology was not overlooked in the face of predominant psychiatric symptoms, as had happened in her local district general acute hospital and psychiatric services.

The natural history of her symptoms was not typical of catatonic schizophrenia, depressive stupor or a dissociative state. Most notably, there was no evidence of psychotic features or low mood prior to onset of the condition and the decline was persistent rather than intermittent as would be expected in a dissociative state.

We also noted the familial enmeshment and unresolved conflicts between patient and parents, which we felt may impact on the patient’s recovery.

### Psychiatric interventions

The psychiatric interventions involved a one-to-one registered mental health nurse relationship to manage agitation and risk of non deliberate harm to self and others, ongoing assessment of mental state and interactions with family and assistance with personal care needs. No psychotropic medication was given.

Initially, the patient’s family, particularly her mother, was spending over 12 h on the ward each day, attending to all her personal care, including feeding and toileting. On the face of it, the family had an overwhelming desire to care. Upon reflection by the team, several interpretations for this devoted approach were considered. There was noted to be a pre-established pattern of infantilizing the patient. For example, the difficulties and debts she had accrued were swiftly taken care of by the parents, rather than being addressed in a manner that would have included the patient.

The family had always been very closely involved with the patient, to the point where the patient appeared to willfully keep some aspects of her life private. The devoted care may have represented an unconscious desire to remain the all-important provider to their child, or to avoid the impending conflict when the patient became well. The family may have been consciously compensating for guilt that may have arisen from inadvertently contributing to their daughter’s presentation by placing too great a level of burden upon her to achieve and conform to their expectations. As well as this, they may have been venting their anger towards the patient’s ex-partner, previous healthcare professionals or the patient’s university via the process of sublimation. The response to their unwell family member was entirely understandable and, on the face of it, caring and appropriate; however, the enthusiasm with which they met the patient’s personal care needs was thought to be perpetuating her withdrawal. The patient’s recovery may, therefore, have been impeded as her instinctive motivation to resume self-care would have been repeatedly met by negative reinforcement in the form of assistance from her family. Alternatively, we hypothesized that maintenance of the sick role served to legitimize the patient’s distress and also as a means of avoidance of the difficulties she had faced and would continue to face upon recovery.

During our involvement with the patient, she received the following treatments from the treating neurology team:

- Immunoglobulin 20 g for 5 days intravenously (iv.);
- Methylprednisolone initially 500 mg iv. and subsequently 1 g iv. for 3 days;
- Azathioprine initially 25 mg once daily, gradually increased up to 125 mg;
- Prednisolone 60 mg once daily;
- Human albumin 3 l daily iv.;
- Plasma exchange.

The treatments were administered serially, and the response initially appeared minimal. Over the course of several weeks, and as described later, the patient slowly and steadily regained various aspects of her functioning.

### Joint mental health & medical nursing care plan

We worked closely with the neurology team to ensure that while the appropriate investigations

took place, there was a consistent behavioral approach to the patient's functional recovery, and that her presentation was considered using a bio–psycho–social model. We used a 'joint nursing care plan' for both the mental health and medical nursing staff to follow. The care plan provided clear guidance as to which members of staff were responsible for the various aspects of care, and also as to how certain foreseeable events should be managed. We spent much time explaining the rationale for giving responsibilities of self-care back to the patient in a graded way. We engaged the family by asking them to help increase the patient's daily repertoire of activities (e.g., by watching television, listening to music, walking on the ward or to the coffee shop and allowing the patient some independent time). The family was still able to contribute to caring for their family member, but negative reinforcements of the patient's helplessness and 'sick role' were avoided and replaced with helpful strategies for promoting functional recovery.

---

### Diagnosis

Most of the differential diagnoses were swiftly excluded. It was thought not be psychosis on account of the fact that symptoms began to resolve without the administration of an anti-psychotic of either a therapeutic dose or period. The initial positive investigations were suggestive of NMS; however, the history and in particular the chronology indicated that NMS was not the only explanation, nor the cause for the initial presentation. As the more-specialist investigations were awaited, the preferred diagnosis remained NMS upon a background of autoimmune encephalitis. The Neuroimmunology Laboratory in Oxford, UK, subsequently confirmed a diagnosis of anti-NMDA receptor encephalitis via assay. On account of the fact that anti-NMDA receptor encephalitis is not known to elevate CPK, further weight was given to the likelihood of NMS having occurred as well.

---

### Physical pathology

Encephalitis is an inflammation of the brain parenchyma [1] that may present with headache, fever, photophobia and also seizures. Less commonly, patients may experience slowness of movement, clumsiness and stiffness of their limbs. These usual symptoms were largely absent in this patient.

The patient's diagnosis of anti-NMDA receptor encephalitis is an acute form of encephalitis that

predominantly affects females and is usually associated with tumors, although not always. A review of 100 patients showed that 91 of the 100 sufferers were women, with a mean age of 23 years [2]. As was the case in the patient we describe, all patients presented with psychiatric symptoms or memory problems. Eighty-eight patients developed decreased consciousness and unresponsiveness, 69 patients had autonomic instability, 86 patients had dyskinesias and 58 patients were found to have a tumor upon screening. Seventy-five patients went on to recover or had mild residual symptoms, and 25 patients were left with severe deficits or subsequently died. A second study of 12 patients diagnosed with anti-NMDA receptor encephalitis found 11 of them to have a teratoma of the ovary upon investigation [3].

---

### Discussion

This case highlights the overlap between psychiatry and neurology, not only due to an organic condition presenting with psychiatric symptoms, but also, as highlighted, due to a psychiatric intervention resulting in NMS. It also serves to remind all clinicians of the significance of considering organic causes for psychiatric presentations, particularly in patients presenting with psychiatric symptoms for the first time. Of note is the fact that, along with psychosis, anti-NMDA receptor encephalitis can affect relatively young patients [4]. Frequently, young women with teratomas of the ovary develop changes of mood, behavior and personality, resembling acute psychosis [5]. The majority of patients with anti-NMDA receptor encephalitis develop a multistage illness that progresses from psychosis, memory deficits, seizures and language disintegration into a state of unresponsiveness with catatonic features [6]. The clinical picture usually progresses to also include decreased levels of consciousness, dyskinesias, autonomic instability and hypoventilation [5]. The initial presentation served to convince the admitting medical team that this patient was suffering from a psychiatric illness, such that her records would indicate that she did not receive a thorough physical assessment at her first presentation to A&E. She was discharged to the community crisis psychiatric services, resulting in her organically caused symptoms deteriorating over the course of approximately 1 month. By the time our service assessed her, we documented her as suffering from 'facial twitches', which in retrospect were likely to be orofacial choreiform movements often seen in

patients with anti-NMDA receptor encephalitis. As well as this, in the case of our patient, the prescription of psychiatric medication led to the rare but iatrogenically caused NMS, which has been shown to carry a mortality rate of up to 38.5% in patients with an organic brain syndrome [7], and is more likely to occur in patients with mental retardation, psychomotor changes and dehydration [8,9].

Prior to her diagnosis, the patient had achieved first-class results in her first year at university. She now complains of poor concentration and short-term memory, and neuropsychological assessment has confirmed residual deficits in cognitive function. She has impairments in working memory, processing speed, performance and verbal domains, as well as executive functioning. She has received cognitive rehabilitation sessions focused on executive skills including study skills, multitasking, time management and problem solving; however, she has not returned to her degree course and it is thought unlikely that she will be able to complete her course at this time.

She is living with her parents but able to carry out all personal care tasks independently. Her family has been willing to reflect on the contribution of the family dynamics throughout the patient's illness and, with education, were able to act as cofacilitators in her recovery on the ward. They will now be embarking on a course of family therapy.

An out-patient abdomen and pelvis ultrasound scan was organized for this patient by the neurology team, the results of which are not currently known.

#### Financial & competing interests disclosure

*The authors have no relevant affiliations or financial involvement with any organization or entity with a financial interest in or financial conflict with the subject matter or materials discussed in the manuscript. This includes employment, consultancies, honoraria, stock ownership or options, expert testimony, grants or patents received or pending, or royalties.*

*No writing assistance was utilized in the production of this manuscript.*

#### References

- Longmore M, Wilkinson I, Torok E. *Oxford Handbook of Clinical Medicine*. Oxford University Press, UK, 359 (2001).
- Dalmau J, Gleichman AJ, Hughes EG *et al*. Anti-NMDA-receptor encephalitis: case series and analysis of the effects of antibodies. *Lancet Neurol*. 7(12), 1091–1098 (2008).
- Dalmau J, Tüzün E, Wu HY *et al*. Paraneoplastic anti-N-methyl-D-aspartate receptor encephalitis associated with ovarian teratoma. *Ann. Neurol*. 61(1), 25–36 (2007).
- Gable MS, Gavali S, Radner A. Anti-NMDA receptor encephalitis: report of ten cases and comparison with viral encephalitis. *Eur. J. Clin. Microbiol. Infect. Dis*. 28(12), 1421–1429 (2009).
- Florance NR, Davis RL, Lam C *et al*. Anti-N-methyl-D-aspartate receptor (NMDAR) encephalitis in children and adolescents. *Ann. Neurol*. 66(1), 11–18 (2009).
- Dalmau J, Lancaster E, Martinez-Hernandez E, Rosenfeld MR, Balice-Gordon R. Clinical experience and laboratory investigations in patients with anti-NMDAR encephalitis. *Lancet Neurol*. 10(1), 63–74 (2011).
- Shalev A, Hermesh H, Munitz H. Mortality from neuroleptic malignant syndrome. *J. Clin. Psychiatry* 50(1), 18–25 (1989).
- Viejo LF, Morales V, Puñal P, Pérez JL, Sancho RA. Risk factors in neuroleptic malignant syndrome. A case–control study. *Acta Psychiatr. Scand*. 107(1), 45–49 (2003).
- Adnet P, Lestavel P, Krivosic-Horber R. Neuroleptic malignant syndrome. *Br. J. Anaesth*. 85(1), 129–135 (2000).